


Consensus statement on the management of incidentally discovered FDG avid thyroid nodules in patients being investigated for other cancers

Jonathan Wadsley¹  | Sabapathy P. Balasubramanian² | Gitta Madani³ | Jean Munday⁴ | Tom Roques⁵ | Christopher W. Rowe⁶ | Philip Touska⁷ | Kristien Boelaert⁸

¹Weston Park Cancer Centre, Sheffield, UK

²Sheffield Teaching Hospitals, Sheffield, UK

³Imperial College Healthcare NHS Trust, London, UK

⁴Queen Alexandra Hospital, Portsmouth, UK

⁵Norfolk and Norwich Hospital, Norwich, UK

⁶University of Newcastle, Newcastle, New South Wales, Australia

⁷Guy's and St Thomas' Hospital, London, UK

⁸University of Birmingham, Birmingham, UK

Correspondence

Jonathan Wadsley, Weston Park Cancer Centre, Whitham Rd, Sheffield S10 2SJ, UK.
Email: jonathan.wadsley1@nhs.net

Abstract

With the widespread use of 18F-fluorodeoxyglucose positron emission tomography (FDG PET/CT) in the investigation and staging of cancers, incidental discovery of FDG-avid thyroid nodules is becoming increasingly common, with a reported incidence in the range 1%–4% of FDG PET/CT scans. The risk of malignancy in an incidentally discovered FDG avid thyroid nodule is not clear due to selection bias in reported retrospective series but is likely to be less than 15%. Even in cases where the nodule is found to be malignant, the majority will be differentiated thyroid cancers with an excellent prognosis even without treatment. If, due to index cancer diagnosis, age and co-morbidities, it is unlikely that the patient will survive 5 years, further investigation of an incidental FDG avid thyroid nodule is unlikely to be warranted. We provide a consensus statement on the circumstances in which further investigation of FDG avid thyroid nodules with ultrasound and fine needle aspiration might be appropriate.

KEYWORDS

FDG PET, prognosis, thyroid incidentaloma

1 | INTRODUCTION

Owing to the widespread use of 18F-fluorodeoxyglucose positron emission tomography (FDG PET/CT) in the investigation and staging of cancers, incidental discovery of FDG-avid thyroid nodules (thyroid incidentaloma [TI]) is becoming an increasingly common phenomenon. It is now typical for specialist thyroid cancer multidisciplinary team (MDT) meetings to receive regular referrals of such cases.

The following multicenter multidisciplinary consensus statement seeks to provide guidance to clinicians involved with the care of these patients regarding when further investigation of TI is warranted, and, perhaps more importantly, when it is not required.

A group of opinion leaders in Oncology, Endocrine Surgery, Head and Neck Radiology and Endocrinology came together to consider

whether imaging can be reduced and a less invasive approach adopted to FDG avid nodules in patients with a very poor prognosis due to another cancer. We searched the literature and based on relevant literature and on the clinical expertise of the panel, formulated a consensus statement.

2 | BACKGROUND

2.1 | Incidence, risk of malignancy and risk of thyroid cancer-related death

The incidence of TI on FDG PET/CT varies between 1% and 4% in most studies and up to 2.5% in meta-analyses.^{1–4} Focal FDG uptake is associated

with thyroid nodules which have an increased risk of malignancy¹ and the 2014 BTA guidelines classify FDG-avid nodules as high-risk nodules.⁵ It must, however, be remembered that the prognosis of the illness for which the FDG PET/CT has been undertaken (e.g., staging of lung cancer) will, in many cases, be significantly worse than that of a small, incidentally discovered thyroid cancer. If the patient is unlikely to survive more than 5 years from their index malignancy, further investigation is unlikely to be warranted.

A meta-analysis of 22 studies concluded that the risk of malignancy in FDG-avid TI is around 35% and most malignant TI are differentiated thyroid cancers (DTC).⁶ However, the risk of malignancy in FDG-avid TI is probably not as high as suggested by the meta-analysis due to selection bias, since only around half of the FDG-avid nodules in the included studies were assigned a diagnosis. In studies where a large majority of FDG-avid TI underwent follow-up, the reported prevalence of malignancy was generally lower (around 15%).^{2,3} Furthermore, in one large series of 1730 FDG PET/CT scans, TI were found in 65 (3.8%), but thyroid cancer was only detected in 2 (3%) of these.⁷

Another large series found TI in 1003 of 52,693 FDG PET/CT scans (1.9%) with only one thyroid cancer-related death in this cohort.⁸ A further series reported TIs in 500 of 45,680 FDG PET scans (1.1%).⁹ Of these 500 patients, 362 had confirmed death or more than 12 months follow up. Of these 362 patients, there were 180 deaths, most related to the primary malignancy under evaluation. Only one death was related to an incidentally discovered thyroid cancer.

The risk of thyroid cancer-related death in these patient cohorts appears to be extremely low. Even if a TI is found to be a thyroid cancer, given the slow rate of growth of most incidentally detected thyroid cancers, it is unlikely that this will cause significant clinical problems within 5 years.

2.2 | Pattern of FDG-PET uptake

Increased thyroid uptake of the FDG radiotracer may be focal or diffuse.

Diffuse uptake is typically associated with benign inflammatory conditions such as thyroiditis or Graves' disease and is thought to reflect increased metabolism rather than thyroid neoplasia and is not relevant in the context of thyroid neoplasms.¹⁰ The diagnosis can be further supported by clinical or serological studies.¹

Focal uptake is typically of greater concern as it can indicate a malignant nodule.¹¹ However, several benign neoplastic pathologies, such as adenomas (mitochondria-rich oncocytic adenomas in particular) can also exhibit focal uptake.^{4,12-14}

Nodules with visually intense FDG uptake have been associated with higher rates of malignancy in some, but not all, studies.^{1,2,15,16} Studies and meta-analyses have also demonstrated higher maximum standardised uptake values (SUVmax) in malignant (as compared to benign) nodules.^{1,4,17} Larg et al.¹⁸ demonstrated substantially higher SUVmax in metastatic TIs than thyroid carcinoma and the results were statistically significant. However, there is variation in the findings of studies and overlap between SUVmax of benign and

malignant nodules. SUVmax is also influenced by technical factors. This precludes defining an SUVmax cut-off for malignancy but most of the available data suggests that intensely FDG avid nodules are more likely to be malignant.¹ In the absence of a clear cut-off, visual assessment is the most useful tool; TIs are usually defined as focal uptake greater than the background thyroid. Focal thyroid uptake which is greater than that of normal liver parenchyma, mediastinal blood pool or two to three times greater than the background thyroid would generally be considered an intensely FDG avid TI.¹⁸

The discordant results of various studies are very likely because the diagnostic and management pathways and resection rates are variable. Despite the heterogeneous results in the literature, markedly FDG avid thyroid nodules (where FDG uptake is markedly increased compared to the liver or 2-3 times that of the background thyroid) with indeterminate or suspicious ultrasound features (U3-5) should undergo fine needle aspiration, if clinically appropriate, even if the nodule is small because the risk of malignancy is higher.¹¹

2.3 | Correlation with pathology

DTC account for 95% of thyroid cancers.¹⁹ Papillary thyroid cancer is the most common subtype of differentiated thyroid cancer and generally has an excellent prognosis. It has been established that the PET avidity in papillary and follicular thyroid cancers is inversely related to iodine avidity.²⁰ The extent of dedifferentiation in thyroid cancers appears to correlate with reduction in iodine avidity and increase in FDG avidity.^{20,21} The risk of local invasion, nodal metastases, or distant metastases is low in DTC that measure less than 4 cm.²²

Follicular, oncocytic cell and poorly DTC are deemed to be higher risk, with a propensity for haematogenous spread to the lungs and bones. These tumours are generally avid on FDG PET/CT,²⁰ supporting the notion that avid nodules are more likely to be malignant.

Follicular and oncocytic thyroid cancers commonly have indeterminate (British Thyroid Association [BTA] U3) ultrasound features. However, it should be noted that most BTA U3 thyroid nodules are benign.²³ In non-DTC tumours, the risk of metastases in tumours below 2.5 cm in size is low and mortality increases with tumour size greater than 2.5 cm.²²

Medullary carcinoma accounts for fewer than 5% of thyroid cancers and may be familial or sporadic. Medullary cancer may be, but is not inevitably, FDG avid.²⁴

Thyroid lymphoma and anaplastic carcinoma are uncommon and FDG avid.²⁰ Both are rapidly enlarging tumours which are likely to be symptomatic and unlikely to present as incidentalomas.

Papillary microcarcinomas are tumours measuring ≤ 1 cm in size and are usually clinically silent and found incidentally. Although nodule size is not an indicator of future clinical behaviour, the high prevalence of microcarcinomas at autopsy (up to 36% in one study) suggests that many papillary microcarcinomas are indolent.²⁵

2.4 | Correlation with ultrasound features

Sonographic features of thyroid nodules are widely utilised to determine risk of malignancy.¹¹ Studies have validated nodule grading systems such as the BTA U-grading and TIRADS as reliable methods of evaluating malignancy with a high (up to 99.8%) negative predictive value.^{23,26} Therefore, nodules graded as U2 are highly likely to be benign.

Yoon et al. demonstrated that risk stratification of TI based on ultrasound features increased the specificity and positive predictive value for the detection of malignancy.²⁷ Other studies demonstrate that benign (BTA U2, EU-TIRADS 2) ultrasound features in TIs are highly predictive of benign cytology. One retrospective series revealed that of 24 FDG-avid nodules with no suspicious US features, 91.6% had benign cytology, 8.3% were indeterminate and none were malignant.²⁸ Another retrospective series reported that of 75 patients with TI on FDG PET, no patients categorised as EU-TIRADS 2 had thyroid cancer.²⁹ Therefore, TIs with benign ultrasound features do not require fine needle aspiration or ultrasound follow-up.

2.5 | Further investigation

TSH measurement is advisable for all TI so that any coexisting thyroid dysfunction may be detected and treated appropriately. A low TSH may indicate hyperthyroidism, which could be due to a functional thyroid nodule, which can be established using thyroid technetium isotope scintigraphy. Functional thyroid nodules are rarely malignant.

A decision to carry out FNA of a TI should not be taken lightly. A substantial minority of patients who undergo FNA proceed to diagnostic surgery, the majority of whom have benign disease. The investigation and treatment of thyroid nodules is associated with patient anxiety and morbidity.^{30,31}

3 | CURRENT GUIDELINES

Existing thyroid cancer management guidelines provide limited guidance on the appropriate investigation of FDG avid thyroid nodules. Notably, recently published UK NICE Guidelines on Thyroid cancer: assessment and management³² do not comment on this issue.

(i) BTA 2014.⁵

3.1 | BTA 2014 guidelines

Nodules detected by PET-CT with focal FDG activity should be investigated with ultrasound and FNAC, unless disseminated disease is identified and the prognosis from an alternative malignancy would preclude further investigation.

(ii) American Thyroid Association 2015.³³

3.2 | ATA 2015 guidelines

3.2.1 | Section A4

With the discovery of a thyroid nodule > 1 cm in any diameter or diffuse or focal thyroidal uptake on F18-fluorodeoxyglucose positron emission tomography (18FDG-PET) scan, a serum TSH level should be obtained. If the serum TSH is subnormal, a radionuclide thyroid scan should be obtained to document whether the nodule is hyperfunctioning ('hot', i.e., tracer uptake is greater than the surrounding normal thyroid), iso-functioning ('warm', i.e., tracer uptake is equal to the surrounding thyroid), or nonfunctioning ('cold', i.e., has uptake less than the surrounding thyroid tissue).

3.2.2 | Section A7

- (A) *Focal 18FDG-PET uptake within a sonographically confirmed thyroid nodule conveys an increased risk of thyroid cancer, and fine needle aspiration is recommended for those nodules \geq 1 cm (strong recommendation, moderate-quality evidence).*
- (B) *Diffuse 18FDG-PET uptake, in conjunction with sonographic and clinical evidence of chronic lymphocytic thyroiditis, does not require further imaging or fine needle aspiration (strong recommendation, moderate-quality evidence).*

4 | RECOMMENDATIONS

4.1 | General approach

- Consider the patient's age, long-term prognosis, co-morbidities, and PET characteristics of the thyroid nodule, taking into account the patient's understanding of their prognosis and any uncertainty around this, when deciding whether to investigate a TI. **If it is likely that the patient will not survive 5 years, further investigation is unlikely to be appropriate.** Should the prognosis subsequently be revised to be more favourable, the appropriateness of further investigation should be considered by the clinician responsible for on-going follow up.

Decision to investigate a TI with ultrasound

- Specific thyroid investigation and follow-up is not required in patients with a short life expectancy (less than 5 years due to comorbid illnesses) unless
 - o the TI is believed to be a metastasis which would affect treatment of the known cancer.
 - o the TI is greater than 4 cm in size and has significant FDG-uptake, where there is concern that local progression of

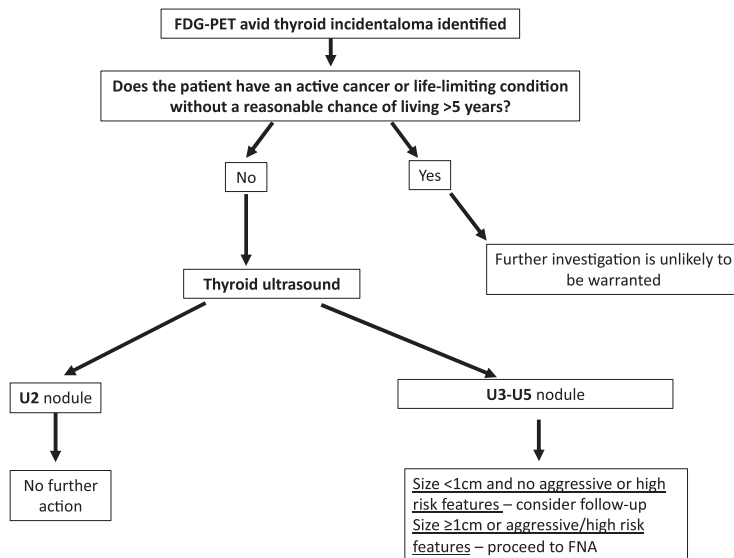


FIGURE 1 Algorithm for investigation of fluorodeoxyglucose avid thyroid incidentaloma.

an undiagnosed thyroid malignancy may cause significant morbidity.

- o the TI is greater than 4 cm and/or could be the source of the patient's metastatic disease.
- Recommend risk stratification with US of an FDG-avid TI in patients who have a reasonable life expectancy (greater than 5 years).

Decision to perform FNA biopsy

FNA is not needed for a TI with benign (U2) ultrasound appearances.

- Perform FNA for U3, U4 and U5 TI if the TI measures ≥ 1 cm
- Consider FNA for U3-5 TI < 1 cm if there are high risk or aggressive features: FNA sampling of subcentimetre nodules may be warranted in young patients, in nodules with intense uptake (greater than liver parenchymal uptake or 2–3 times greater than background thyroid) or high-risk ultrasound features (such as irregular outline, taller than wide shape), extrathyroidal extension and/or cervical lymphadenopathy potentially attributable to thyroid metastases). In other patients, no action (or occasionally ultrasound follow-up) should be considered.

Figure 1 provides a suggested algorithm to guide the investigation of FDG avid TI.

5 | CONCLUSIONS

With the widespread use of FDG PET/CT in the investigation and staging of many cancers, the finding of incidental focal FDG uptake in the thyroid is becoming increasingly common. Recent literature suggests that the risk of thyroid malignancy in these TIs is lower than had been suggested in previous case series (which had selection bias), and that the risk of death from thyroid malignancy in this scenario is very low (1 patient of 500 with TIs in one series).⁴

We therefore recommend that if a patient is unlikely to survive 5 years as a result of their index cancer or other co-morbidities, further investigation is unlikely to be required except in specific circumstances outlined in this consensus statement. If further investigation is required this will be with ultrasound imaging in the first instance, and where indicated FNA cytology.

This consensus statement does not replace sound clinical judgement. Clinical decisions must be based on patient's individual circumstances.

ORCID

Jonathan Wadsley  <https://orcid.org/0000-0002-1499-1277>

REFERENCES

1. Soelberg KK, Bonnema SJ, Brix TH, Hegedüs L. Risk of malignancy in thyroid incidentalomas detected by 18F-fluorodeoxyglucose positron emission tomography. A systematic review. *Thyroid*. 2012;22:918-925.
2. Chen YK, Ding HJ, Chen KT, et al. Prevalence and risk of cancer of focal thyroid incidentaloma identified by 18F-fluorodeoxyglucose positron emission tomography for cancer screening in healthy subjects. *Anticancer Res*. 2005;25(2B):1421-1426.
3. Thuillier P, Roudaut N, Crouzeix G, et al. Malignancy rate of focal thyroid incidentaloma detected by FDG PET-CT: results of a prospective cohort study. *Endocr Connect*. 2017;6(6):413-421.
4. Bertagna F, Treglia G, Piccardo A, Giubbini R. Diagnostic and clinical significance of F-18-FDG-PET/CT thyroid incidentalomas. *J Clin Endocrinol Metab*. 2012;97(11):3866-3875.
5. Perros P, Colley S, Boelaert K, et al. British Thyroid Association Guidelines for the management of thyroid cancer. *Clin Endocrinol*. 2014;81(suppl 1):1-122.
6. Treglia G, Bertagna F, Sadeghi R, Verburg FA, Ceriani L, Giovanella L. Focal thyroid incidental uptake detected by ¹⁸F-fluorodeoxyglucose positron emission tomography. *Nuklearmedizin*. 2013;52(4):130-136.
7. Elzein S, Ahmed A, Lorenz E, Balasubramanian S. Thyroid incidentalomas on PET imaging—evaluation of management and clinical outcomes. *Surgeon*. 2015;13(2):116-120.
8. Piek MW, de Boer JP, Vriens MR, et al. Retrospective analyses of 18FDG-PET/CT thyroid incidentaloma in adults: incidence,

- treatment, and outcome in a tertiary cancer referral center. *Thyroid*. 2021;31(11):1715-1722.
9. Pattison DA, Bozin M, Gorelik A, Hofman MS, Hicks RJ, Skandarajah A. 18F-FDG-Avid thyroid incidentalomas: the importance of contextual interpretation. *J Nucl Med*. 2018;59:749-755.
 10. Agrawal K, Weaver J, Ngu R, Krishnamurthy Mohan H. Clinical significance of patterns of incidental thyroid uptake at ¹⁸F-FDG PET/CT. *Clin Radiol*. 2015;70:536-543.
 11. de Leijer JF, Metman MJH, van der Hoorn A, et al. Focal thyroid incidentalomas on ¹⁸F-FDG PET/CT: a systematic review and meta-analysis on prevalence, risk of malignancy and inconclusive fine needle aspiration. *Front Endocrinol*. 2021;12:723394.
 12. Hassan A, Riaz S, Asif A. Hypermetabolic hurthle cell adenoma on ¹⁸F-FDG PET/CT. *Mol Imaging Radionucl Ther*. 2018;27(2):96-98.
 13. Poller DN, Megadmi H, Ward MJA, Trimboli P. Hürthle cells on fine-needle aspiration cytology are important for risk assessment of focally PET/CT FDG avid thyroid nodules. *Cancers*. 2020;12(12):3544.
 14. Kresnik E, Gallowitsch HJ, Mikosch P, et al. Fluorine-18-fluorodeoxyglucose positron emission tomography in the pre-operative assessment of thyroid nodules in an endemic goiter area. *Surgery*. 2003;133(3):294-299.
 15. Kim BH, Na MA, Kim IJ, Kim SJ, Kim YK. Risk stratification and prediction of cancer of focal thyroid fluorodeoxyglucose uptake during cancer evaluation. *Ann Nucl Med*. 2010;24(10):721-728.
 16. Thuillier P, Bourhis D, Roudaut N, et al. Diagnostic value of FDG PET-CT quantitative parameters and deauville-like 5 point-scale in predicting malignancy of focal thyroid incidentaloma. *Front Med*. 2019;6:24.
 17. Pathak KA, Goertzen AL, Nason RW, Klonisch T, Leslie WD. A prospective cohort study to assess the role of FDG-PET in differentiating benign and malignant follicular neoplasms. *Ann Med Surg*. 2016;12:27-31.
 18. Larg Apostu, Apostu Gabora, Peştean Olariu, et al. Evaluation of malignancy risk in 18F-FDG PET/CT thyroid incidentalomas. *Diagnostics*. 2019;9:92.
 19. Cabanillas ME, McFadden DG, Durante C. Thyroid cancer. *Lancet*. 2016;388(10061):2783-2795.
 20. Marcus C, Whitworth PW, Surasi DS, Pai SI, Subramaniam RM. PET/CT in the management of thyroid cancers. *Am J Roentgenol*. 2014;202(6):1316-1329.
 21. Choudhury PS, Gupta M. Differentiated thyroid cancer theranostics: radioiodine and beyond. *Br J Radiol*. 2018;91(1091):20180136. doi:10.1259/bjr.20180136
 22. Nguyen XV, Roy Choudhury K, Tessler FN, Hoang JK. Effect of tumor size on risk of metastatic disease and survival for thyroid cancer: implications for biopsy guidelines. *Thyroid*. 2018;28(3):295-300.
 23. Al-Chalabi H, Karthik S, Vaidyanathan S. Radiological-pathological correlation of the British Thyroid Association ultrasound classification of thyroid nodules: a real-world validation study. *Clin Radiol*. 2019;74:702-711.
 24. Ozkan ZG, Kuyumcu S, Uzum AK, et al. Comparison of 68Ga-DOTATATE PET-CT, 18F-FDG PET-CT and 99mTc-(V)DMSA scintigraphy in the detection of recurrent or metastatic medullary thyroid carcinoma. *Nucl Med Commun*. 2015;36(3):242-250.
 25. Harach HR, Franssila KO, Wasenius VM. Occult papillary carcinoma of the thyroid. A "normal" finding in Finland. A systematic autopsy study. *Cancer*. 1985;56:531-538.
 26. Chng C, Tan H, Too C, et al. Diagnostic performance of ATA, BTA and TIRADS sonographic patterns in the prediction of malignancy in histologically proven thyroid nodules. *Singapore Med J*. 2018;59(11):578-583.
 27. Yoon JH, Cho A, Lee HS, Kim EK, Moon HJ, Kwak JY. Thyroid incidentalomas detected on 18F-fluorodeoxyglucose-positron emission tomography/computed tomography: Thyroid Imaging Reporting and Data System (TIRADS) in the diagnosis and management of patients. *Surgery*. 2015;158(5):1314-1322.
 28. Beech P, Lavender I, Jong I, et al. Ultrasound stratification of the FDG-avid thyroid nodule. *Clin Radiol*. 2016;71(2):164-169.
 29. Trimboli P, Paone G, Treglia G, et al. Fine-needle aspiration in all thyroid incidentalomas at ¹⁸F-FDG PET/CT: can EU-TIRADS revise the dogma? *Clin Endocrinol*. 2018;89(5):642-648.
 30. Pitt SC, Saucke MC, Wendt EM, et al. Patients' reaction to diagnosis with thyroid cancer or an indeterminate thyroid nodule. *Thyroid*. 2021;31(4):580-588.
 31. Moon N, Jeong Y-J, Jeon T-H, et al. The degree of anxiety before taking biopsies in patients with thyroid nodules. *Korean J Fam Pract*. 2015;5(3):253-258.
 32. NICE Guideline [NG230] *Thyroid Cancer: Assessment and Management*. <https://www.nice.org.uk/guidance/ng230>
 33. Haugen BR, Alexander EK, Bible KC, et al. 2015 American Thyroid Association Management Guidelines for adult patients with thyroid nodules and differentiated thyroid cancer: the American Thyroid Association Guidelines Task Force on thyroid nodules and differentiated thyroid cancer. *Thyroid*. 2016;26(1):1-133.

How to cite this article: Wadsley J, Balasubramanian SP, Madani G, et al. Consensus statement on the management of incidentally discovered FDG avid thyroid nodules in patients being investigated for other cancers. *Clin Endocrinol*. 2023; 1-5. doi:10.1111/cen.14905